

Clinical Study

Cytokine evaluation in individuals with low back pain using discographic lavage

Jason M. Cuellar, MD, PhD^a, S. Raymond Golish, MD, PhD^b, Merrill W. Reuter, MD, PhD^c,
Vanessa G. Cuellar, MD^a, Martin S. Angst, MD^d, Eugene J. Carragee, MD^b,
David C. Yeomans, PhD^d, Gaetano J. Scuderi, MD^{b,*}

^aNew York University Hospital for Joint Diseases, New York, NY 10003, USA

^bDepartment of Orthopaedic Surgery, Stanford University, Redwood City, CA 94063, USA

^cPrivate Practice, Lake Worth, FL 33460, USA

^dDepartment of Anesthesia, Stanford University, Stanford, CA 94305, USA

Received 18 February 2009; revised 20 November 2009; accepted 14 December 2009

Abstract

BACKGROUND CONTEXT: The pathophysiology underlying degenerative disc disease and its implication in painful syndromes remain unclear. However, spine magnetic resonance imaging (MRI) can demonstrate changes in disc water content and the annulus; provocative discography purportedly identifies degenerate discs causing serious low back pain; and biochemical assays have identified local inflammatory markers. No study to date has correlated pain on disc injection during discography evaluation with relevant MRI findings and biochemical markers.

PURPOSE: The purpose of this study was to correlate concordant pain on during discography to biochemical markers obtained by disc lavage and MRI findings.

STUDY DESIGN: This is a Phase 1 Diagnostic Test Assessment Cohort Study (Sackett and Haynes).

PATIENT SAMPLE: The patient sample included 21 symptomatic patients with suspected discogenic pain and three Phase 1 control subjects.

OUTCOME MEASURES: The outcome measures included discography pain scores, MRI degenerative grades, and immunoreactivity to various inflammatory cytokine concentrations present in disc lavage samples.

METHODS: Twenty-one symptomatic patients with lumbar degenerative disc disease and three control subjects underwent discography, MRI, and biochemical analysis of disc lavage fluid. Lumbar MRI was scored for Pfirrmann grading of the lumbar discs, and annular disruption was identified by nuclear disc lavage. Disc lavage samples were analyzed for biochemical markers by high-sensitivity immunoassay.

RESULTS: Eighty-three discs from 24 patients were studied: 67 discs from 21 patients with axial back pain (suspected discogenic pain group) and 16 discs from 3 scoliosis patients without back pain (Phase 1 control subjects). Among the biochemical markers surveyed, interferon gamma (IFN- γ) immunoreactivity was most consistently identified in patients with axial back pain. Discs

FDA device/drug status: not applicable.

Author disclosures: JMC (stock ownership, including options and warrants, Cytonics; scientific advisory board, Cytonics; research: staff/materials, Cytonics); SRG (stock ownership, including options and warrants, Cytonics Inc; scientific advisory board, Cytonics); MWR (stock ownership, including options and warrants, Cytonics; private investments, including venture capital, start-ups, Cytonics); VGC (stock ownership, including options and warrants, Cytonics Corp; scientific advisory board, Cytonics Corp); MSA (royalties, Stanford University; stock ownership, including options and warrants, Cytonics; consulting, Trigemina Inc, Cortex Inc, Vertex Inc; scientific advisory board, Cytonics Inc; research: investigator salary, Scientific Imagination; research: staff/materials, Scientific

Imagination); EJC (consulting, Medtronic; scientific advisory board, Intrinsic Orthopedics, Cytonics; other office, Bioassetts; grants, AO Foundation; fellowship support, DePuy Spine); DCY (stock ownership, including options and warrants, Cytonics Inc; scientific advisory board, Cytonics, Inc); GJS (stock ownership, including options and warrants, Cytonics Corp; private investments, including venture capital, start-ups, K2 Medical; board of directors, Cytonics; scientific advisory board, Cytonics; other office, Chairman).

* Corresponding author. Department of Orthopaedic Surgery, Stanford University, Redwood City, CA, 94063.

E-mail address: scuderimd@aol.com (G.J. Scuderi)

with annular disruption and concordant pain reproduction at a visual analog scale of 7 to 10/10 had greater IFN- γ immunoreactivity than those without this finding ($p=.003$); however, at least some IFN- γ immunoreactivity was found in all but one disc in the symptomatic group.

CONCLUSIONS: Among the potential inflammatory markers tested in this Phase 1 study, IFN- γ immunoreactivity was most commonly elevated in discogram “positive” discs but absent in asymptomatic controls. However, this marker was also frequently elevated in degenerative but “negative” discography discs. From these findings, Phase 2 and Phase 3 validity studies are reasonable to pursue. Phase 4 utility studies may be performed concurrently to assess this method’s predictive value in outcome studies. © 2010 Elsevier Inc. All rights reserved.

Keywords:

Intervertebral disc; Cytokines; Interferon gamma; Discography; Low back pain

Introduction

Chronic low back pain (LBP) remains a challenging condition to treat. Medical expenditures by Americans with axial back pain syndromes rose approximately 65% from 1997 to 2005 [1]. Although imaging studies, such as magnetic resonance imaging (MRI), can be used to document pathologic and age-related changes in the spine, studies have shown a poor correlation between MRI findings and clinical presentation. Rates of disc degeneration and herniation increase with normal aging and do not consistently result in pain [2]. Discography, which emerged as a potential diagnostic test to determine if discs were a primary source of axial pain, has demonstrated limited success [3]. Alternative strategies have suggested that it may be the presence of specific inflammatory mediators that determines if a disc is clinically painful.

Although few previous studies have measured inflammatory markers in discs *in vivo* [4], several *in vitro* studies have postulated a role for various cytokines in disc-related pain syndromes [5–14]. Tumor necrosis factor- α and interleukin (IL)-8 have been identified in surgical disc specimens removed for the treatment of pain [4,11]. Kang et al. [12] identified matrix metalloproteinase, nitric oxide, prostaglandin E2, and IL-6 in cultures of discs retrieved in patients with a lumbar disc herniation and radiculopathy. Similarly, Takahashi et al. [13] identified IL-1-beta, IL-6, and tumor necrosis factor- α in prepared tissue specimens from retrieved human herniated disc tissue. Burke et al. [14] identified high levels of both IL-6 and IL-8 in patients with symptomatic degenerative disc disease who underwent spinal fusion. It has been postulated that even a small amount of these factors may be sufficient enough to initiate an inflammatory process after rupture of the nucleus pulposus because of their ability to recruit other cytokine-producing cells and stimulate the upregulation of genes coding for proinflammatory mediators [15].

Newer methods for rapid and sensitive cytokine detection have since been developed. We hypothesized that provocative discography and/or radiographic change on MRI would correlate to specific inflammatory mediators detected in the disc space by using a highly sensitive protein immunoassay on samples obtained during disc lavage.

Methods

This study was performed from June 2006 to June 2008. Institutional review board approval was obtained according to Health and Human Services Guidelines, and patients provided informed consent at the time of enrollment.

Symptomatic subjects’ screening

Twenty-one patients ranging in age from 21 to 75 years with axial back pain of at least 6 months’ duration were enrolled in this study (study group). The patients were identified among 119 consecutive patients offered study enrollment for the evaluation of their chronic pain. This cohort was drawn from a single board-certified orthopedic surgeon trained in spine surgery (G.J.S.). Patients with a history of oral or injected corticosteroid medication within a 3-month period before discography and those with chronic medical conditions associated with metabolic or inflammatory disorders (insulin-dependent diabetes mellitus, severe coronary artery disease, and rheumatic or autoimmune diseases) were excluded from the study.

Demographic information was obtained including gender, age, insurance, work status, and reported pain on a visual analog scale (VAS) of 0 to 10 before the procedure. Provocative discography, recording annular disruption, pain intensity, and concordance for each disc injected, was performed by an experienced discographer.

A blinded analysis of MRI was performed with each injected disc level classified according to the Pfirrmann grading scale [16] by a board certified radiologist.

Phase 1 control subjects

A Phase 1 Diagnostic Validity Control (ie, application of test in subjects definitively known not to have the index disease) by Sackett and Haynes Criteria [17] was also performed using disc lavage samples from asymptomatic subjects and adolescents undergoing surgical treatment for scoliosis deformity. Disc lavage, without subsequent discography contrast injection, was carried out intraoperatively before excision of each disc. Each lavage was done under the supervision of the lead investigator (G.J.S.). As described in the Sackett and Haynes model for assessing diagnostic test validity, this Phase 1 assessment is a necessary,

EVIDENCE & METHODS

Context

There are no unique radiographic or pathologic markers that accurately identify disc pathology that is causing chronic low back pain.

Contribution

In this study of discography lavage, the authors found most inflammatory markers did not correlate with degeneration grade or response to disc injection. Only IFN immunoreactivity was consistently present in patients with low back pain and absent in controls without low back pain; but only modestly correlated with disc injection pain.

Implications

Despite years of investigation, no unique marker or technique has been found to accurately identify primary discogenic pain. Annular fissures, Modic changes, provocative or anaesthetic discography, inflammatory markers, and other candidates have thus far demonstrated poor test validity. This has led some to suggest this search is misdirected (the illness is not primarily structural) and others to suggest the search will be fruitful with the emergence of newer technologies.

While the current findings are intriguing, it is unclear if IFN is simply a marker for degeneration (rather than painful degeneration) and if disc puncture and lavage is a safe and reproducible sampling method. However, these results suggest further exploration is reasonable.

—The Editors

but not sufficient, first screening for test validity. That is, if the test is positive in this group (ie, the finding of a specific cytokine at high concentrations), this will provide evidence against test validity.

Disc lavage technique

All symptomatic study participants underwent lumbar discography to evaluate their chronic axial pain. The patient was placed prone on a radiolucent table and prepared using standard sterile procedure. Intravenous antibiotics were given before the commencement of discography. After infiltrating the subcutaneous tissue with 1% xylocaine with epinephrine, a 22-gauge needle was used to enter the annulus, followed by fluoroscopic placement confirmation. Approximately 1 to 3 mL of sterile physiologic saline was injected into each disc space, and the lavage fluid was immediately withdrawn back into the same syringe, yielding ~0.5 mL of lavasate, which was then placed into 2-mL Eppendorf tubes containing a protease inhibitor cocktail tablet (Roche Diagnostics, Indianapolis, IN, USA) dissolved in phosphate-buffered saline to reach a total volume of 130 μ L (~0.045 tablet/mL per sample) and immediately frozen at -20° C. Samples

were then transported to the laboratory where the fluid was stored at -80° C until analysis.

A nucleogram with Omnipaque was performed at all levels considered as potential pain sites, in addition to a “control” injection at a level with negative findings on MRI in each subject. Pain provocation, intensity, concordance, and annular disruption were recorded.

The Bio-Plex system (BioRad, Hercules, CA, USA), a multiplex bead array immunoassay, was used for analysis of lavasate. This system uses a sandwich-style immunoassay with capture antibodies linked to polystyrene beads and detection antibodies conjugated to fluorophores. It has been validated against standard enzyme-linked immunosorbent assays in human blood [18]. The immunoreactivity (immunofluorescence) of 17 cytokines/chemokines (interferon gamma [IFN- γ], IL-2, IL-4, IL-5, IL-6, IL-7, IL-8, IL-10, IL-12, IL-13, IL-17, granulocyte colony-stimulating factor, granulocyte macrophage colony-stimulating factor, tumor necrosis factor- α , IL-1 β , MCP-1, and macrophage inflammatory protein-1Beta (MIP-1 β) was measured using the pre-mixed human inflammatory 17-plex panel. Each multiplex assay was performed in duplicate and according to the manufacturer’s specifications. Standard curves were included in each run, and sample concentrations were calculated with Bio-Plex Manager software from these fluorescence measurement curves.

Statistical analysis

Statistical analyses were performed with SPSS v.14 (SPSS Inc., Chicago, IL, USA). The study was designed by a prior power analysis. For $N=67$ discs (study group analysis), the power of the t test of significance of the Pearson correlation statistic with an alpha value of 0.05 is 99.7% for a large effect size (Pearson $r=0.5$). The power of the chi-square test of a two-by-two contingency table analysis with an alpha value of 0.05 is 98.4% for a large effect size (w statistic=0.5). The power of the F test of significance of multiple regression with an alpha value of 0.05 is 99.2% for a large effect size (F^2 statistic=0.35).

Results

A total of 83 discs from 24 patients were studied: 67 discs from 21 patients with LBP (study group) and 16 discs from 3 Phase 1 control subjects (scoliosis patients) with no pain.

In the LBP group, there were 13 men and nine women with mean age 44 ± 11 years (range 20–64) and mean pre-operative VAS of 7.4 ± 1.3 . In the LBP groups, IFN- γ was the only cytokine tested that was consistently identified, with mean (\pm standard deviation), median, and range of immunoreactivity corresponding to a concentration of 276 ± 455 , 136, and 4.7–2,814.0 pg/mL, respectively. Of the other 16 cytokines, mean and median calculated concentrations were zero except for IL-2 (mean= 1.3 ± 1.7 ,

median=0.6, range=0–9.3) and granulocyte macrophage colony-stimulating factor (mean=11.1±20.8; median=0; range = 0–83.8).

In the asymptomatic control group, there were two males and one female with mean age of 16±0.6 years (range 15–16). The mean (±standard deviation) and median concentration of IFN-γ were 2.7±6.1 and 0.4 pg/mL, respectively (range 0.0–23.0).

The level of IFN-γ detected in lavage samples from discs of symptomatic subjects was significantly greater than that detected in discs from asymptomatic control subjects (p=.003; one-way analysis of variance [ANOVA] controlling for age) (Fig. 1).

Analysis of IFN-γ immunoreactivity in symptomatic subjects

In the symptomatic group, IFN-γ concentrations were consistent with an exponential (log₁₀) distribution but not a normal distribution (Fig. 2; p <0.001). Subsequent regression and correlation analyses were therefore performed with log₁₀ (IFN-γ) concentrations. The results did not change with the use of untransformed IFN-γ concentrations.

Analysis of IFN-γ concentrations with respect to the pain intensity rating during provocative discography results was performed (Fig. 2). Using a cutoff pain intensity value of 6 (as recommended by Walsh et al. [19]) to separate positive from negative painful injection, there was no significant difference in IFN-γ concentrations by t test (Fig. 3; p=.43). Using a cutoff pain intensity value of 7 (as

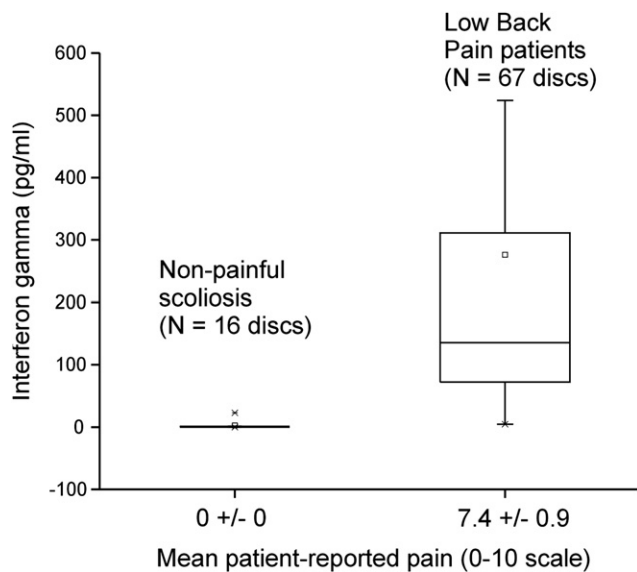


Fig. 1. A comparison of interferon gamma concentration in picograms per milliliter (pg/ml; on a log scale) between patients with low back pain (N=67 discs) who underwent discography and those without back pain (asymptomatic scoliosis controls; N=16 discs). The error bars represent the standard error of the mean. The difference is significant by one-way analysis of variance controlling for age (p=.008).

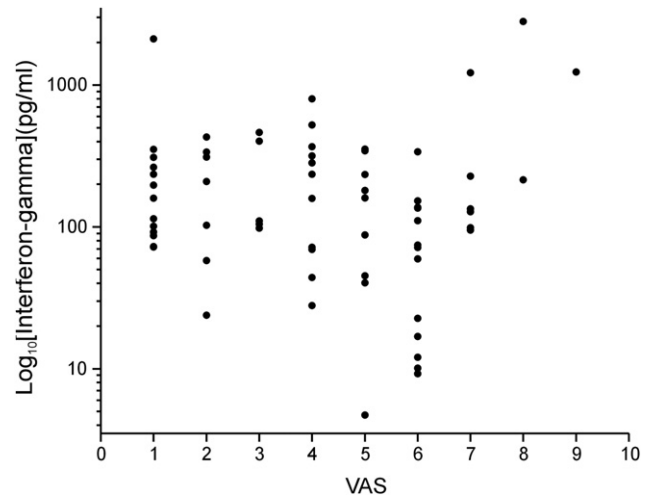


Fig. 2. A scatter plot showing interferon gamma concentration in picograms per milliliter (pg/ml; on a log scale) from all lavage samples taken during discograms of patients with axial pain. Patient-reported pain during discography was rated on a visual analog scale (VAS) of 1 to 10 and is represented on the x-axis.

recommended by Derby et al. [20]), there was a significant difference in IFN-γ concentrations (Fig. 3; p=.003).

These results did not change (ie, significance obtained with a cutoff value of 7 but not with 6) using a matched analysis in which IFN-γ levels were normalized (either by subtraction or division) by the “control level” of the discogram (ie, the level tested by discogram with the lowest intra-operative VAS score) or with the use of log₁₀ IFN-γ measurements. There was no significant correlation between IFN-γ concentration and injection pain intensity with ANOVA or log-linear analysis with the use of main effects and two-way effects when the data were not dichotomized into painful versus not painful groups with a cutoff value.

Analysis of IFN-γ versus Pfirrmann grade on MRI

Analysis of IFN-γ concentrations with respect to Pfirrmann grade on MRI was performed (Fig. 4) using a grouping of grades 1 to 2 as mild, grades 3 to 4 as moderate, and grade 5 as severe. There was no significant difference in IFN-γ concentration by t test. The results did not change with the use of log₁₀ IFN-γ measurements, with the use of ANOVA or log-linear analysis using main effects and two-way effects when the data were not dichotomized painful and not painful groups with a cutoff value, or with a matched analysis in which IFN-γ levels were normalized (by either subtraction or division) by the “control level” of the discogram (ie, the level tested by discogram with the lowest Pfirrmann MRI grade).

Analysis of discography versus MRI findings

Statistical analysis of the relationship between discography and MRI findings was undertaken irrespective of IFN-γ concentration (Table 1). In the study group, there were no

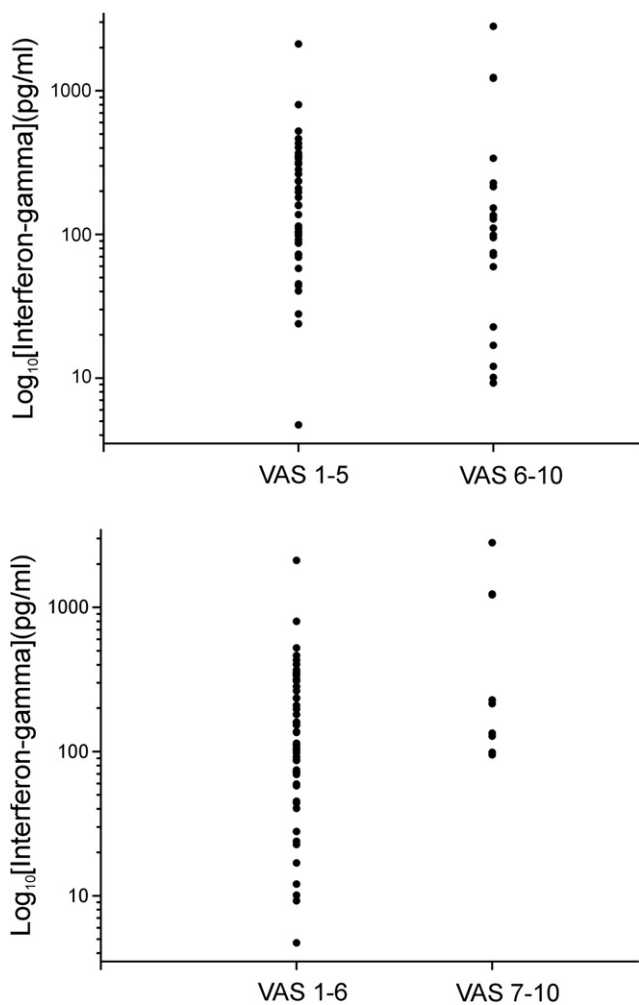


Fig. 3. (Top) A comparison of interferon gamma (IFN- γ) concentration in picograms per milliliter (on a log scale) between patients with self-reported pain on discography rated on a visual analog scale (VAS) of 1 to 10, grouped by VAS of 1 to 5 and 6 to 10, with mean IFN- γ concentration (\pm standard error of the mean) of 246 ± 48 and 342 ± 145 , respectively. The differences are not significant by *t* test ($p=.43$). (Bottom) A comparison of IFN- γ concentration in picograms per milliliter (on a log scale) between patients with pain on discography grouped by visual analog scale of 1 to 6 and 7 to 10, with mean (\pm standard error of the mean) IFN- γ concentration of 213 ± 39 and 686 ± 309 , respectively. The differences are significant by *t* test ($p=.003$).

significant correlations (either bivariate marginal or trivariate partial) among provocative discogram pain intensity with injection (VAS) and Pfirrmann MRI grade by Pearson correlation (p value greater than .05). The results did not change with the use of Spearman correlations, ANOVA, or log-linear analysis or with the use of main effects and two-way effects.

Discussion

Our understanding of the pathophysiology of axial back pain on a molecular level continues to evolve but remains an area of active investigation. On a clinical level,

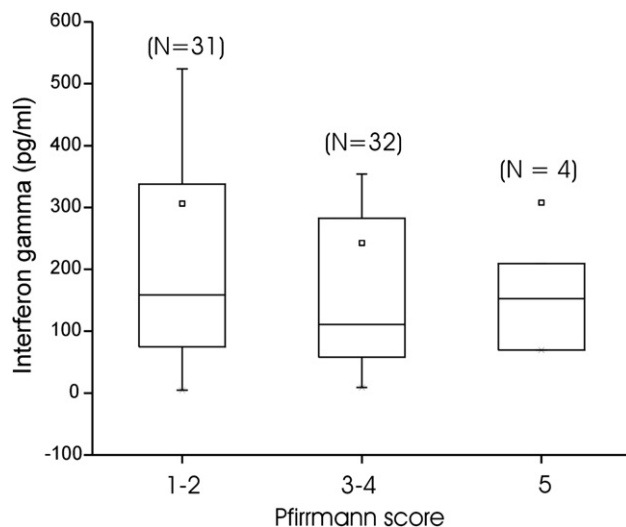


Fig. 4. A comparison of interferon gamma concentration in picograms per milliliter (on a log scale) among patients with magnetic resonance imaging changes graded by Pfirrmann scores 1 to 2, 3 to 4, and 5. The error bars represent the standard error of the mean. The differences are not significant by analysis of variance ($p=.77$).

differentiating the subset of discs that may cause seriously painful back disability from either normal aging or clinically painless degeneration is similarly difficult. Provocative discography and MRI are tests that physicians consider in identifying an underlying source of back pain. However, recent studies suggest that discography and MRI are at best modestly predictive of outcomes following interventions directed at suspected “discogenic” pain [19]. In light of these limitations, a clinical assay of biochemical markers to complement other diagnostic modalities is desirable.

The study provides a Sackett and Haynes Phase 1 analysis of a possible diagnostic test for identifying discogenic pain. This first-stage diagnostic test assessment is intended to survey the results of lavage technique quantification of inflammatory markers in discs from subjects suspected to have discogenic pain and compare these to the findings in discs definitively without discogenic pain (asymptomatic scoliosis subjects) and discs highly unlikely to be the

Table
Summary of statistical analysis among intraoperative provocative discogram visual analog scale (VAS; 1–10 scale), magnetic resonance imaging Pfirrmann grade (1–5 scale), and preoperative VAS (1–10 scale)

Grade Scale	Intraoperative VAS	MRI Pfirrmann grade	Preoperative VAS
Intraoperative VAS	—	$r=0.07$; $p=.59$	$r=0.12$; $p=.35$
MRI Pfirrmann grade		—	$r=0.16$; $p=.20$
Preoperative VAS			—

Data are Pearson correlation (r) and p values; there are no significant differences (p value greater than .05). The results do not change with the use of Spearman correlations.

source of discogenic pain (morphologically normal discs without pain on disc injection in LBP symptomatic subjects). It should be emphasized that this Phase 1 study cannot provide a high confidence in positive test validity. However, if the test were repeatedly positive in discs and subjects without discogenic pain, then the *prima facie* evidence would indicate that this is very unlikely to be a valid test with Phase 2 or Phase 3 investigations.

The present study showed mixed results. IFN- γ immunoreactivity was the most consistent positive assay detected in the lavage fluid of discs sampled in symptomatic subjects. Higher levels of IFN- γ immunoreactivity were obtained from discs with the greatest pain response on disc injection. However, some IFN- γ immunoreactivity (greater than 10 pg/mL) was detected in all but one disc in the symptomatic group, even from those discs with relatively normal MRI findings or an apparently “negative control” discography designation. On the other hand, the samples from disc lavage in the asymptomatic group did not show appreciable IFN- γ immunoreactivity.

Although various inflammatory cytokines have been identified in the intervertebral disc as it undergoes degeneration, it is not known if any of these specific inflammatory chemicals plays a significant role in axial LBP [13,21–23]. Inflammatory cytokines have been previously identified in cerebrospinal fluid of patients with symptomatic degenerative disc disease, although the source and concentration of inflammatory mediators at the level of the symptomatic nerve root are unknown [7,24]. It has been postulated that inflammatory mechanisms are most likely involved in the painful state in axial pain syndromes [4,6,24,25]. Identification of matrix fragments, nonenzymatic glycation products, and neuropeptides is representative of the many ongoing products and processes that occur with aging and degeneration but does not necessarily generate pain [26].

A practical sampling technique for specific biomarkers that may accurately predict serious LBP generated intrinsic to that disc would greatly help our understanding of symptomatic degenerative disc disease and perhaps direct appropriate clinical care. Although further research with more detailed biochemical peptide analyses to delineate its role is required to confirm our findings, this study suggests that IFN- γ immunoreactivity may be an important clinical biomarker for some axial pain syndromes associated with common degenerative findings.

It is interesting that our preliminary data suggest that the correlation between discography findings, MRI findings, and levels of biochemical markers of inflammation was not strong in this patient population using this sampling technique. This finding may reflect the heterogeneity of cytokine concentrations in different parts of the disc. The lavage technique will necessarily retrieve substances preferentially from the nuclear center, as opposed to the subannular or subligamentous space. Spot sampling in the epidural space or along the annulus or in specific

annular fissures may yield different results. It is also probable that some LBP syndromes with common degenerative findings may be because of primarily mechanical or other processes without a strong intradiscal inflammatory component.

In conclusion, this study suggests that IFN- γ immunoreactivity from a disc lavage sampling has at least preliminary Phase 1 assessment support for potential test validity in discogenic pain. From these findings, Phase 2 and Phase 3 validity studies are reasonable to pursue. Phase 4 utility studies may be performed concurrently to assess this method's predictive value in outcome studies.

References

- [1] Martin BI, Deyo RA, Mirza SK, et al. Expenditures and health status among adults with back and neck problems. *JAMA* 2008;299:656–64.
- [2] Boden SD, Davis DO, Dina TS, et al. Abnormal magnetic-resonance scans of the lumbar spine in asymptomatic subjects. A prospective investigation. *J Bone Joint Surg Am* 1990;72:403–8.
- [3] Carragee EJ, Lincoln T, Parmar VS, Alamin T. A gold standard evaluation of the “discogenic pain” diagnosis as determined by provocative discography. *Spine* 2006;31:2115–23.
- [4] Igarashi T, Kikuchi S, Shubayev V, Myers RR, et al. 2000 Volvo Award winner in basic science studies: exogenous tumor necrosis factor- α mimics nucleus pulposus-induced neuropathology. Molecular, histologic, and behavioral comparisons in rats. *Spine* 2000;25:2975–80.
- [5] Scuderi GJ, Brusovanik GV, Golish SR, et al. A critical evaluation of discography in patients with lumbar intervertebral disc disease. *Spine J* 2008;8:624–9.
- [6] Saal JS, Franson RC, Dobrow R, et al. High levels of inflammatory phospholipase A2 activity in lumbar disc herniations. *Spine* 1990;15:674–8.
- [7] Hyyppa MT, Alaranta H, Lahtela K, et al. Neuropeptide converting enzyme activities in CSF of low back pain patients. *Pain* 1990;43:163–8.
- [8] Lindh C, Thornwall M, Hansen AC, et al. Neuropeptide-converting enzymes in cerebrospinal fluid: activities increased in pain from herniated lumbar disc, but not from coxarthrosis. *Acta Orthop Scand* 1996;67:189–92.
- [9] Imasato H, Nagata K, Hashimoto S, et al. Objective evaluation of pain in various spinal diseases: neuropeptide immunoreactivity in the cerebrospinal fluid. *Spinal Cord* 1997;35:757–62.
- [10] Ahn SH, Cho YW, Ahn MW, et al. mRNA expression of cytokines and chemokines in herniated lumbar intervertebral discs. *Spine* 2002;27:911–7.
- [11] Olmarker K, Rydevik B. Selective inhibition of tumor necrosis factor- α prevents nucleus pulposus-induced thrombus formation, intraneural edema, and reduction of nerve conduction velocity: possible implications for future pharmacologic treatment strategies of sciatica. *Spine* 2001;26:863–9.
- [12] Kang JD, Georgescu HI, McIntyre-Larkin L, et al. Herniated lumbar intervertebral discs spontaneously produce matrix metalloproteinases, nitric oxide, interleukin-6, and prostaglandin E2. *Spine* 1996;21:271–7.
- [13] Takahashi H, Suguro T, Okazima Y, et al. Inflammatory cytokines in the herniated disc of the lumbar spine. *Spine* 1996;21:218–24.
- [14] Burke JG, Watson RW, McCormack D, et al. Intervertebral discs which cause low back pain secrete high levels of proinflammatory mediators. *J Bone Joint Surg Br* 2002;84:196–201.
- [15] Koes BW, Sholten R, Mens J, Bouter LM. Epidural steroid injection for low back pain and sciatica: an updated systematic review of randomized clinical trials. *Pain Digest* 1999;9:241–7.
- [16] Pfirmann CW, Metzendorf A, Zanetti M, et al. Magnetic resonance classification of lumbar intervertebral disc degeneration. *Spine* 2001;26:1873–8.

- [17] Sackett SL, Haynes RB. The architecture of diagnostic research. *BMJ* 2002;324:539–41.
- [18] de Jager W, te Velthuis H, Prakken BJ, et al. Simultaneous detection of 15 human cytokines in a single sample of stimulated peripheral blood mononuclear cells. *Clin Diagn Lab Immunol* 2003;10:133–9.
- [19] Walsh TR, Weinstein JN, Spratt KF, et al. Lumbar discography in normal subjects. A controlled, prospective study. *J Bone Joint Surg Am* 1990;72:1081–8.
- [20] Derby R, Kim BJ, Lee SH, et al. Comparison of discographic findings in asymptomatic subject discs and the negative discs of chronic LBP patients: can discography distinguish asymptomatic discs among morphologically abnormal discs? *Spine J* 2005;5:389–94.
- [21] Gronblad M, Virri J, Tolonen J, et al. A controlled immunohistochemical study of inflammatory cells in disc herniation tissue. *Spine* 1994;19:2744–51.
- [22] Goupille P, Jayson MI, Valat JP, Freemont AJ. The role of inflammation in disk herniation-associated radiculopathy. *Semin Arthritis Rheum* 1998;28:60–71.
- [23] Carlton SM, Hargett GL. Stereological analysis of Ca(2+)/calmodulin-dependent protein kinase II alpha-containing dorsal root ganglion neurons in the rat: colocalization with isolectin Griffonia simplicifolia, calcitonin gene-related peptide, or vanilloid receptor 1. *J Comp Neurol* 2002;448:102–10.
- [24] Brisby H, Olmarker K, Larsson K, et al. Proinflammatory cytokines in cerebrospinal fluid and serum in patients with disc herniation and sciatica. *Eur Spine J* 2002;11:62–6.
- [25] Olmarker K. Radicular pain—recent pathophysiologic concepts and therapeutic implications. *Schmerz* 2001;15:425–9.
- [26] Kang JD, Stefanovic-Racic M, McIntyre LA, et al. Toward a biochemical understanding of human intervertebral disc degeneration and herniation. Contributions of nitric oxide, interleukins, prostaglandin E2, and matrix metalloproteinases. *Spine* 1997;22:1065–73.